



MOHS SURGERY

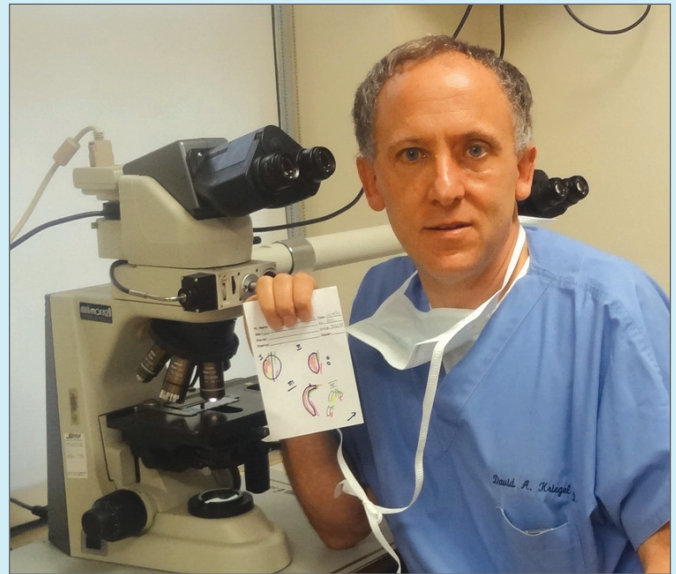The Most Effective Approach to Skin Cancer

By David A. Kriegel, MD

More than two million Americans are diagnosed with skin cancer every year. Of the many different types of cancer that affect the skin, two account for the vast majority of cases: basal cell carcinoma (BCC) and squamous cell carcinoma (SCC). For the most part, these can be prevented by limiting sun exposure, always using sunscreens for outdoor activities, and avoiding indoor tanning.

Yearly skin cancer screening and follow-up treatment by a dermatologist help to detect dangerous skin lesions and keep them from spreading. Between yearly screenings, I advise patients to examine their skin every three or four months, using mirrors to look at their backs and scalps. Most cases of BCC and SCC can be cured if caught early enough.

continued on page 3



A tissue map enables Mohs surgeons like Dr. Kriegel to remove cancerous cells while preserving the surrounding normal skin.

Medical Advances for Uneven Skin Tone

By Angela J. Lamb, MD



Dr. Angela Lamb

“Patients are often as bothered by postinflammatory hyperpigmentation as they are by pimples.”

Discoloration of the skin is a common dermatological problem. Two of its main causes are dark spots resulting from acne, called postinflammatory hyperpigmentation, and tan or brown patches that affect mostly women, a condition known as melasma.

One of the most frequent reasons to visit a dermatologist is for treatment of acne. Though acne can be controlled, the healing process sometimes causes dark marks, particularly for patients of deeper skin tones. Patients are often as bothered by postinflammatory hyperpigmentation as they are by pimples (*see photos on page 4*).

Although the dark spots are distressing, there *are* treatment options. Our first goal is to manage the patient’s acne and prevent additional discoloration. Before we try to attack hyperpigmentation, I encourage patients to adhere to acne treatment for at least eight to twelve weeks, so they’re not getting many new blemishes.

I prefer an acne regimen that includes topical drugs with intrinsic lightening properties. Topical retinoids, which are the mainstay of acne treatment, help the top layers of the skin to turn over faster, releasing some of the excess pigment and thus producing a more uniform skin tone. A topical antibacterial agent called azelaic acid helps to inhibit the biosynthesis of a brown pigment called melanin

continued on page 4

In This Issue

KEEPING YOUR SKIN SAFE IN THE TROPICS
Douglas D. Altchek, MD
Page 2

SKIN CANCER NEWS: NONSURGICAL DIAGNOSIS
Orit Markowitz, MD
Page 5

A WRINKLE CURE FOR THE WINTER BLUES?
Gary Goldenberg, MD
Page 6

Look for Skin Health at www.MountSinaiDermatology.com



AN INTERVIEW WITH DR. DOUGLAS ALTCHERK

about Tropical Dermatology

Q. *From a dermatological point of view, what should travelers know before going to a tropical climate?*

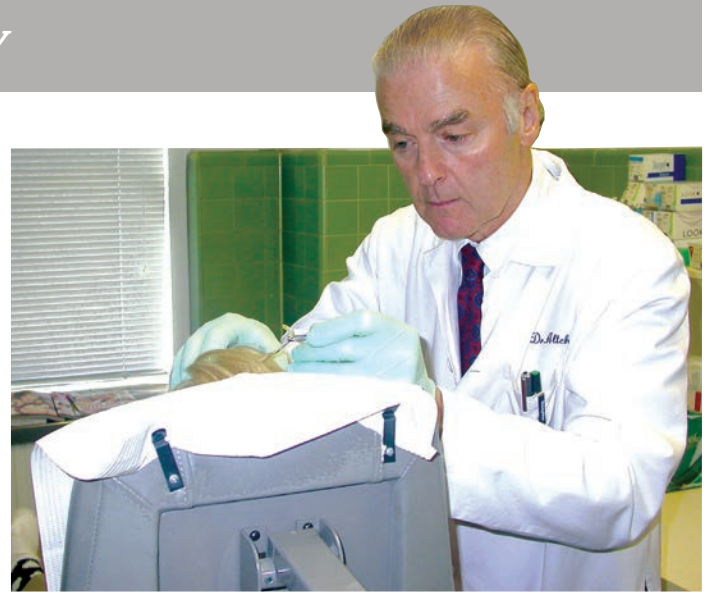A. The greatest danger to the skin is overexposure to the sun. The severity of a sunburn correlates with the risk of developing skin cancer later. Aside from sunburn, the tropical traveler should take precautions against insect bites and exposure to numerous bacterial, fungal, viral, and parasitic diseases.

Q. *What are some of the specific skin disorders you've seen in patients returning from the tropics?*

A. I've treated returning travelers for scabies, creeping eruption, myiasis (botflies), sand fleas (also called chiggers or jiggers), tinea versicolor (a superficial fungus), bacterial infections, and contact dermatitis caused by a range of parasites from caterpillars to fire ants.

Q. *How commonly do you see tropical diseases in New York City?*

A. Because travel to exotic areas is widespread today, tropical diseases are common. According to the American Academy of Dermatology, at least 10% of travelers to the tropics develop skin problems. It is not unusual to see tropical diseases in New York City, because the majority of exposed patients develop symptoms after returning, or they may wait until their return before seeking care.



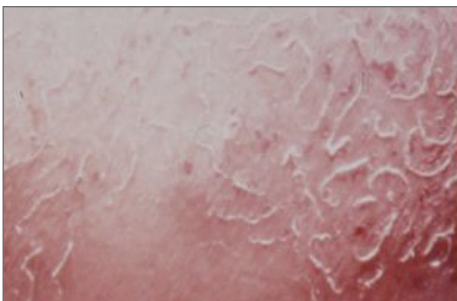Dr. Altchek is shown extracting botfly larvae from the scalp of a patient with myiasis.

Q. *Are tropical diseases difficult to treat and cure?*

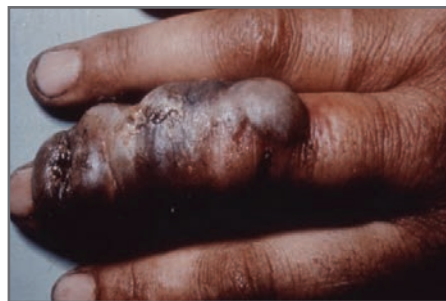A. Most skin diseases contracted in the tropics can be treated rapidly and effectively with oral medications when parasites are the cause and with topical lotions for most cases of fungus. Dermatologists might need to surgically remove parasites, as in the case of botflies (see photo above).

Q. *What specific precautions should one consider when packing for a tropical vacation?*

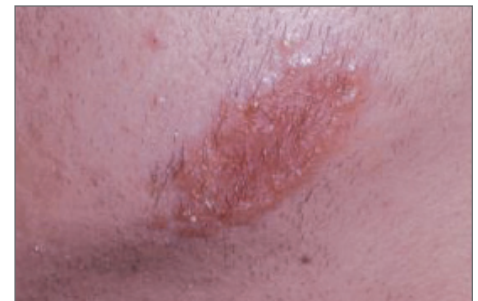A. Protective measures should include sunscreen with SPF 50+ and, depending on the destination, such items as mosquito netting, protective clothing, insect repellent for skin and clothing, and always common sense. Also, don't forget about protection from sexually transmitted diseases. Just because you are on vacation, it doesn't mean you have to take unusual risks.



Tinea imbricata, a fungal infection, occurred after nude sunbathing.



A case of anthrax was acquired at a ranch in South America.



Leishmaniasis, a parasitic infection, resulted from a sandfly bite.

Dr. Altchek is a Clinical Professor of Dermatology; a Voluntary Attending; and Archivist of the Department of Dermatology (www.mssm.edu/altchek).

The Most Effective Approach to Skin Cancer (continued from page 1)

There are several surgical techniques to remove BCCs and SCCs, including wide excisions and destructive methods. These are often effective but don't offer the best cure rates and can leave scars that are larger than necessary. Mohs surgery, a micrographic technique, has the highest success rate, with approximately 98% long-term cure. This procedure is the preferred method for operating on the face and other sensitive areas because of its precision and microscopic accuracy. It allows us to remove all the diseased tissue while sacrificing only a minimal amount of normal skin at the edges of the cancer.

Mohs micrographic surgery is performed on an outpatient basis using local anesthesia. After the area has been numbed, a Mohs surgeon removes the visible tumor along with a thin layer of surrounding tissue. This process usually takes three to five minutes. The specimen is prepared, placed on slides, and treated with special stains in a nearby laboratory, which takes up to an hour. The Mohs surgeon then examines the specimen for cancerous cells. If there is

evidence of residual cancer, its location is marked on a tissue map (*see photos*), and the surgeon removes an additional section of tissue from the patient. The new specimen is then processed in the lab as before, and the surgeon once


“Mohs surgery is the preferred method for operating on the face and other sensitive areas because of its precision and microscopic accuracy.”

again looks for cancerous cells under the microscope. This procedure is repeated until no further cancer is found. Most skin cancers require one to three stages for complete removal.

When Mohs surgery is complete, the surgeon will assess the size, shape, and location of the wound. At this time we customarily advise patients about their options for ideal functional and cosmetic reconstruction. If the defect is small enough, then the wound may be repaired with several stitches to close the deep part of the skin and a few more stitches

to close the superficial layer. If the defect is very large or adjacent to an anatomical structure such as the patient's nose or mouth, a local flap might be performed by cutting and then rotating or advancing enough skin from an adjacent area to cover the defect. Sometimes a skin graft may be recommended. This means removing skin from another body site and transplanting it to cover the surgical wound.

Although Mohs surgery sometimes involves a long day of waiting for lab results, the procedure has significant advantages. It produces a higher cure rate and smaller scar than any other method of skin cancer surgery.



Dr. Kriegel examines a biopsy specimen and uses a tissue map to mark the location of cancer cells.

Dr. Kriegel is an Associate Clinical Professor of Dermatology; Director, Dermatologic and Mohs Surgery; and a member of the Mount Sinai Doctors Faculty Practice (www.mssm.edu/kriegel).

Skin Health

A PUBLICATION OF THE MOUNT SINAI
DEPARTMENT OF DERMATOLOGY

SUSAN V. BERSHAD, MD
Editor

YVONNE B. MEYERS
Managing Editor

MARK G. LEBWOHL, MD
*Professor and Chair
Department of Dermatology
President, Editorial Board*

Editorial Board

DOUGLAS D. ALTCHER, MD

JANET NEZHAD BAND, ESQ.

DAVID COLON

JOSÉ GONZALEZ

GERVAISE L. GERSTNER, MD

GARY GOLDENBERG, MD

NORMAN GOLDSTEIN, MD

AHMED HADI, MD

BRUCE E. KATZ, MD

ALBERT M. LEFKOVITS, MD

ELLEN S. MARMUR, MD

STEPHEN VANCE WALL

PATRICIA WEXLER, MD

The editors thank
Mount Sinai Printing Services.

Medical Advances for Uneven Skin Tone (continued from page 1)

within cells known as melanocytes, which are responsible for determining skin color. When acne is under control, it's time to discuss specific therapy for post-inflammatory hyperpigmentation. In my experience, one of the most effective treatments is a compounded lightening cream, which is a mixture composed of a bleaching ingredient, a retinoid agent, and a topical corticosteroid medicine. I also use mild chemical peels that contain either glycolic acid or salicylic acid to help speed the process along. With the right combination of these methods, I've found that skin tone improves much faster than it would if nature took its course.

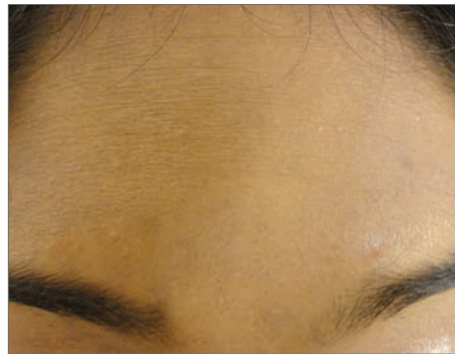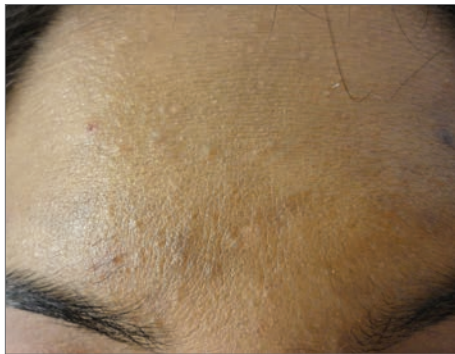Tan or brown-colored facial patches trouble some patients who don't have acne. This is usually melasma, a condition that can be difficult to treat. Female hormones, such as those contained in oral contraceptives or produced during pregnancy, are able to trigger melasma.

We also know that sun exposure contributes to the condition. It's important to determine whether melasma resides in the epidermis, the top layer of skin, or the deeper layer called the dermis. Patches of epidermal melasma are usually dark brown with well-defined borders, and they respond easily to treatment. Dermal melasma consists of lighter brown patches with less precise borders that don't respond as well. There's also a third type of melasma, a combination of the epidermal and dermal types, which can be the most challenging of all.

Once we determine the type of melasma, treatment is customized for the individual patient. Skin-lightening creams, similar to what we use for postinflammatory hyperpigmentation, can be very useful. I've also found the Nd:YAG laser to be quite effective. Other technological advances for uneven skin tone include fractionated lasers and intense pulsed light (IPL) treatments.

Regardless of the course of therapy, the most important piece of advice I can offer to patients with postinflammatory hyperpigmentation or melasma is to apply a broad-spectrum sunscreen every day, regardless of the weather. As the saying goes, an ounce of prevention is worth a pound of cure.

Dr. Lamb is the Director of the Westside Mount Sinai Dermatology Faculty Practice at 638 Columbus Avenue in New York City; an Instructor of Dermatology; and a member of the Mount Sinai Doctors Faculty Practice (www.mssm.edu/lamb).



A patient with acne and postinflammatory hyperpigmentation before (left) and 8 weeks after using topical azelaic acid gel on a nightly basis (right).

**HAPPY NEW YEAR
& MANY THANKS
FOR YOUR
GENEROUS SUPPORT**



All gifts made to the
Department of Dermatology
in 2012 will be listed in the
Spring/Summer 2013
issue of Skin Health.

Please consider a tax-deductible contribution to dermatology research and education.

\$5,000
 \$2,500
 \$1,000
 \$500
 \$250
 \$100
 Other: \$

- My gift is in honor of _____
 I have enclosed my check payable to
 The Mount Sinai Dermatology Fund.



Please charge my gift to:

- Visa
 American Express
 MasterCard

CARD NUMBER _____ EXPIRATION DATE _____

NAME ON CARD _____

SIGNATURE _____

GIVE ONLINE

To make your gift online, please visit us at
<https://philanthropy.mountsinai.org/dermatology>

PLEASE FILL OUT BOTH SIDES

13PUB/13DERMNEWS1

SKIN CANCER DIAGNOSIS WITHOUT SURGERY

According to the Skin Cancer Foundation, one person dies from skin cancer every hour in the United States – a good reason why everyone should schedule regular skin examinations. But you may ask, how do dermatologists know when a skin growth or mole needs to be removed?

In the past, every worrisome skin lesion required a biopsy, meaning a small piece of tissue was surgically removed and sent to a pathology laboratory. If the biopsy showed cancer, additional surgery was needed. Even today, surgical biopsy and removal continues to be the standard of care for skin cancer (see Dr. Kriegel's article on page 1).

How we approach skin biopsies and cancer surgery is changing for the better, thanks to a new technology called Optical Coherence Tomography (OCT). Dr. Orit Markowitz, a pioneer in OCT research, recognizes its potential to eliminate the need for surgery in many cases. Dr. Markowitz is the Director of Pigmented Lesions and Skin Cancer at Mount Sinai, and she is also the newly appointed President of the International Optical Coherence Tomography Society.

“An important component of OCT is a new invention called the VivaScope® Confocal Imager, a laser that takes live pictures

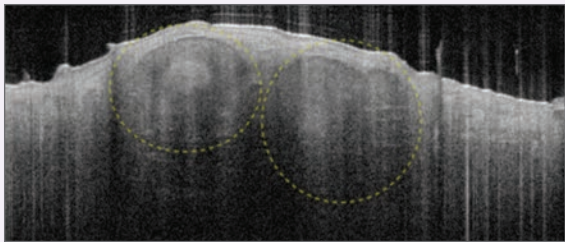
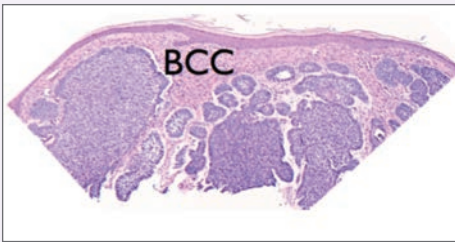
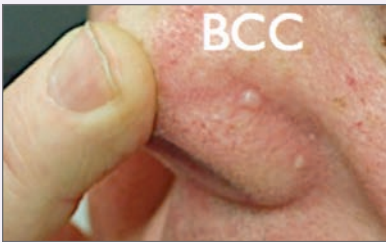of the skin. By combining this device with other lasers, we're discovering ways to diagnose and treat skin cancer bloodlessly,” said Dr. Markowitz. Among the advantages of OCT are improved comfort, greater convenience, and less scarring. Dr. Markowitz's research has enabled Mount Sinai to become the country's leading center for the development and use of OCT.



Dr. Orit Markowitz

According to Dr. Markowitz, “I've also found OCT to be useful for benign skin growths, thus preventing the need for unnecessary biopsies.” She notes some examples: harmless moles, warts, hemangiomas, seborrheic and actinic keratoses, and cysts. Other dermatological diseases that can be diagnosed with OCT include psoriasis, scabies, and blistering diseases.

Dr. Markowitz currently offers OCT and other noninvasive diagnostic techniques to patients at the Mount Sinai Doctors Faculty Practice.



A basal cell carcinoma (BCC) on the nose (left), as it appears in a surgical biopsy specimen (center), and within the encircled areas of an OCT image (right).

Dr. Markowitz is an Assistant Professor of Dermatology; Director, Pigmented Lesions and Skin Cancer; Chief of Dermatology, Queens General Hospital; and a member of the Mount Sinai Doctors Faculty Practice (www.mssm.edu/markowitz).

I'd like news and information from Mount Sinai Dermatology.

Please add me/us to the mailing list of the Department of Dermatology.

Please fill out both sides, detach this form and mail to:

Mount Sinai Dermatology
One Gustave L. Levy Place, Box 1047
New York, NY 10029-6574



TITLE/NAME

ADDRESS

CITY / STATE / ZIP

E-MAIL ADDRESS

()
PHONE



MOUNT SINAI
 ONE GUSTAVE L. LEVY PLACE, BOX 1047
 NEW YORK, NY 10029-6574



Skin Health
 WINTER 2013

RELIEF FOR THE WINTER BLUES?



By Gary Goldenberg, MD

No, it's not a prescription for a vacation in the tropics... it's botulinum toxin injections. Two Maryland researchers, Dr. Eric Finzi and Dr. Erika Wasserman, first reported six years ago that depression was relieved in nine of ten patients who received botulinum toxin for facial frown lines. A 2012 study supported their findings: thirty patients treated with botulinum toxin experienced an average improvement in depression symptoms of nearly 50% on the Hamilton Depression Rating Scale. It makes sense that looking better helps people feel better, but there is more to the story. Scientific evidence suggests that our facial expressions can influence and intensify our

actual emotions. Because botulinum toxin effectively paralyzes the forehead muscles that show sadness and anxiety, some experts believe the wrinkle treatment is able to produce emotional wellbeing beyond the cosmetic benefit.

Dr. Goldenberg is an Assistant Professor of Dermatology and Pathology; and Medical Director of the Mount Sinai Doctors Faculty Practice in dermatology (www.mssm.edu/goldenberg).

F.Y.I. (FOR YOU INSIDE)

- MOHS SURGERY
- SKIN TONE EXPERT
- TROPICAL DISEASES
- DIAGNOSIS WITHOUT SURGERY

To book a dermatology appointment at Mount Sinai Doctors Faculty Practice at 5 East 98th Street or at Westside Mount Sinai Dermatology at 638 Columbus Avenue, please call (212) 241-9728.